

ORIGINAL RESEARCH ARTICLE

OPEN ACCESS

ACTIVE AND CONCRETE EVIDENCES ABOUT SEXUAL REPRODUCTION AND LIFE CYCLE IN THE PARASITIC GENERATION OF *STRONGYLOIDES STERCORALIS* IN HUMAN HOST

*Feleke Eriso

Parasitologist, Department of Biology, Dilla University, Dilla, Ethiopia

ARTICLE INFO

Article History:

Received 22nd April, 2018
Received in revised form
09th May, 2018
Accepted 06th June, 2018
Published online 30th July, 2018

Key Words:

Strongyloidiasis,
Morbidity,
Mortality, Infection,
Fulminant Death.

ABSTRACT

Background: *Strongyloides stercoralis* was believed to have two kinds of life cycle. One of them was an internal parthenogenetic life cycle that constituted the parasitic generation. Some authors also stated that this parasitic generation of the internal life cycle used to reproduce only by protandrogony (i.e., hermaphroditism). The second type of life cycle was the external sexual cycle, interacting among free-living worms that represented the free-living generation in soil. The key objectives of this study were to:

- verify the type of reproduction in the parasitic generation of *S. stercoralis*, and
- establish a complete integrated life cycles of both parasitic and free-living generations of *S. stercoralis*.

Method: The major sites of stool sample collection were selected to be the elementary schools (from students) at Dilla District, because *S. stercoralis* was ascertained to be endemic in this region. The parasitic worms of *Strongyloides stercoralis* obtained from fresh stools were used to set growth culture of free-living generation of this very species and to find the free-living male & female in copulation from the growth culture. A set of parasitic male & female in copulation isolated from a fresh stool sample of a patient under medical care in a hospital was also included.

Result: The male & female worms of *S. stercoralis* had been isolated from both parasitic & free-living generations while they were in the actual copulation. Several males & females of *S. stercoralis* were also isolated from fresh stool samples of student children examined. **Conclusion:** The method of reproduction in the parasitic generation of *S. stercoralis* in human host was practically proved to be certainly sexual. This verified conclusion was the first practical achievement in the entire globe by solving the persistent problems (i.e., erroneous concepts of parthenogenesis and protandrogony as the types of reproduction in the parasitic generation of *S. stercoralis*) that had been misleading and puzzling the minds of the concerned scientists of the world until the establishment of this very achievement. Additionally, this achievement had enabled the investigator to construct the complete integrated life cycles of both parasitic and free-living generations of *S. stercoralis*.

Copyright © 2018, Feleke Eriso. This is an open access article distributed under the Creative Commons Attribution License, which permits unrestricted use, distribution, and reproduction in any medium, provided the original work is properly cited.

Citation: Feleke Eriso, 2018. "Active and concrete evidences about sexual reproduction and life cycle in the parasitic generation of *Strongyloides stercoralis* in human host", *International Journal of Development Research*, 8, (07), 21385-21390.

INTRODUCTION

S. stercoralis is believed to have two kinds of life cycle: an internal parthenogenetic cycle that constitutes the parasitic generation, and the external sexual cycle, representing the free-living generation in soil (Mitrevva *et al.*, 2004; Concha *et al.*, 2005; Hunter *et al.*, 2008). It had been stated that the type of reproduction in the parasitic generation of *S. stercoralis* in

human host was only by parthenogenesis of parasitic females in the absence of parasitic males (Gilles, 1996; Paniker, 2007; Bogitsh, 2005; Dillard, 2007; Keiser, 2004). Due to this concept of parthenogenesis the parasitic male had been omitted in the figures that demonstrated the life cycle of the parasitic generation of *S. stercoralis* in all modern and relevant textbooks, journals, and on the internet. In the parasitic generation, when the filariform larvae are in contact with skin, they penetrate the small cutaneous blood vessels and are carried through the right heart to the lungs (Nolan, 1999). Then, the mature parasitic females settle in the tissues of epithelial mucosa to lay eggs that hatch soon and are

*Corresponding author: Feleke Eriso, m,
Parasitologist, Department of Biology, Dilla University, Dilla,
Ethiopia.

discharged in stools each day (Dionisio *et al.*, 2000; Massey *et al.*, 2003). When all or some larvae metamorphose into infective filariform larvae autoinfection may be onset by invading the mucosa of the ileum or colon, travel to lungs and then return to the intestine to mature in the mucosa (Garg *et al.*, 2005; Siddiqui *et al.*, 2012; Siegel, 2012; Ramanathan, 2008). Disseminated strongyloidiasis had been reported in both of two recipients of kidney allografts from a single cadaver donor (Poonam *et al.*, 1999). It was also reported that in a 53-year-old man who had lung cancer, fulminantly fatal strongyloidiasis had developed following postchemotherapy of immunosuppression, resulting in the death of the patient within 48 hours (Poonam *et al.*, 1999). The development of a florid strongyloidiasis was observed in a 45-year-old man, following anticancer chemotherapy when eggs of *S. stercoralis* were seen in the stools (Jayshree *et al.*, 2001). One scientific study has reported that almost all deaths due to helminth in the United States result from *S. stercoralis* hyperinfection mortality rates because the occurrence of hyperinfection can be as high as 87% (Kim *et al.*, 2005). Concerning some morphological features of this parasite, the part of the worm's body that is known as the tail is the posterior part of body beginning from cloaca in the parasitic males or beginning from anus in the parasitic females. Cloaca is the opening through which spicules are everted at times of copulation and fertilization; and it is also the outlet of the digestive tract. The 3 stages of human strongyloidiasis are:

Intestinal Strongyloidiasis, Gastropulmonary Strongyloidiasis, and Disseminated Strongyloidiasis (Fardet *et al.*, 2007; Kerepesi *et al.*, 2007; Rahif *et al.*, 2002; Cheesbrough, 1998). Some of the clinical presentations (manifestations) of strongyloidiasis can be highlighted as: Cutaneous with larva currens (racing larvae), pruritic linear or serpiginous, creeping urticarial eruption, dermatologic lesions, and petechiae; Pulmonary with persistent wheezing, cough, and deteriorating respiratory status; and Intestinal with vomiting, abdominal pain, watery diarrhea and constipation.

Aim of the study: The aim of this study has two key objectives that are: to prove the fact that the type of reproduction in the parasitic generation of *S. stercoralis* is certainly sexual, and to establish a complete integrated life cycles of both parasitic and free-living generations of *S. stercoralis*.

Patients and Methods: The sites of collecting data were decided to be elementary schools at Dilla District, because *S. stercoralis* was ascertained to be endemic in this region. The purpose of collecting stools samples from different elementary schools was to set growth culture of free-living worms of *S. stercoralis* in sterilized topsoil from which the copulating free-living male (♂) and female (♀) of this species can be isolated. Then, the form of copulation of this set of free-living male & female was planned to be compared with that of parasitic male & female isolated from a fresh stool sample taken from an HIV/AIDS patient under medical care in a hospital. Sample Size. A total of 300 students were randomly examined for *S. stercoralis*. Those children with relatively large number of rhabditiform larvae of this parasite were used as the sources of stools samples for inoculating the worms into the sterilized topsoil in petridishes.

Growth culture of free-living generation: Topsoil that contained organic substance was taken and put into four

different petridishes. Each of the petridishes was closed with its own lid and labeled 1, 2, 3, and 4; and then, the following 4 steps were implemented. The petridishes with their contents of topsoil were autoclaved. The topsoil autoclaved in each of the petridishes was inoculated with fresh stool sample infected with *S. stercoralis* and identified to harbor relatively heavy worm-load of this parasite, before they had been given treatment. Excess water was added to the topsoil of all the four petridishes and were incubated at 28^o C on the same day. With the aim to find the free-living male & female in copulation, using a dropper a drop of soil suspension from each of the four topsoil petridishes incubated was placed on a clean slide & covered with a 22² mm coverslip and examined under a compound light microscope everyday beginning from the 3rd day of incubation until the 5th day.

Treatment: The participant children who were found to be positive for *S. stercoralis* were given 400 mg albendazole tablet to take with a glass of water on empty stomach in the morning and to begin taking meal at noon. This prescription & clinical supervision was performed by a medical doctor (Dr. Corazon B. Jaca FMA).

RESULTS

On the 5th day from the date of setting the growth culture of free-living generation of *S. stercoralis*, the free-living male & female in copulation were found and isolated from the growth culture. The copulating pair was observed under a compound light microscope and microphotographed from the field of vision of the microscope using a digital camera. The copulating pair of the parasitic generation which was isolated from a fresh stool sample of an HIV/AIDS patient was microphotographed from the field of vision of the microscope in the same way with the digital camera. Now, the free-living male & female in copulation, and the parasitic male & female in copulation isolated from a fresh stool sample are spectacularly displayed for comparison.

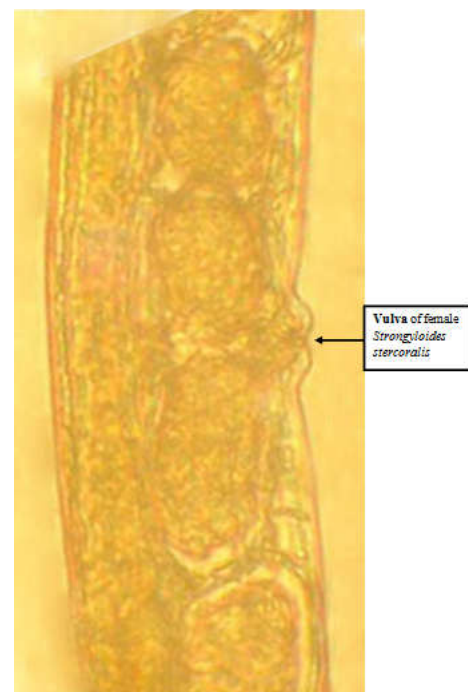

Figure 1. The middle body part of female *Strongyloides stercoralis* with vulva which is located approximately in the middle of body length. Vulva is the exit of female reproductive tract

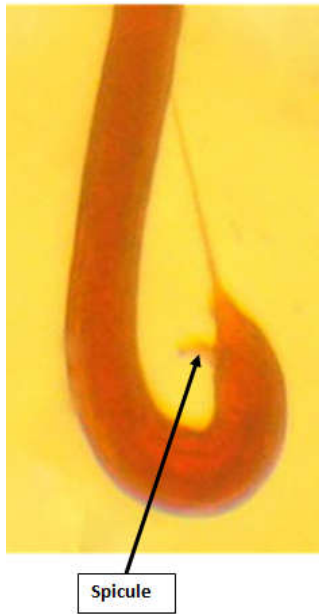

Figure 2a. It is only the posterior body part of male *Strongyloides stercoralis* that is curved

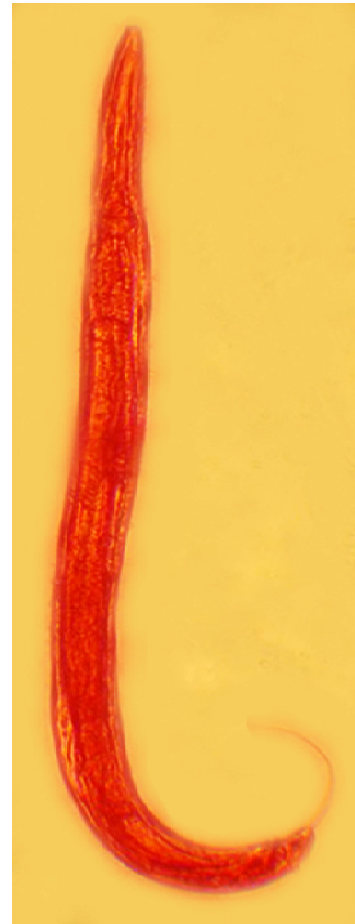


Figure 2d. The curved posterior body part of a male *Strongyloides stercoralis*

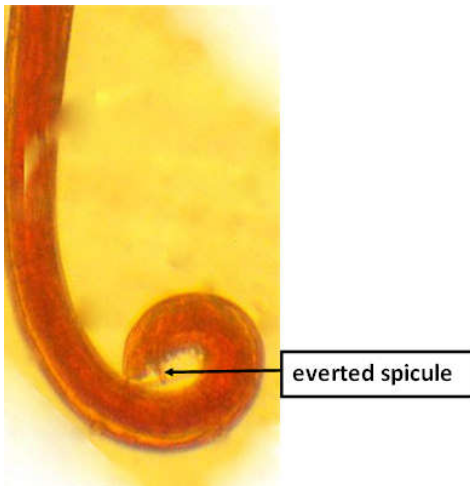


Figure 2b. The curved or “coiled” posterior body part of a male *Strongyloides stercoralis*.

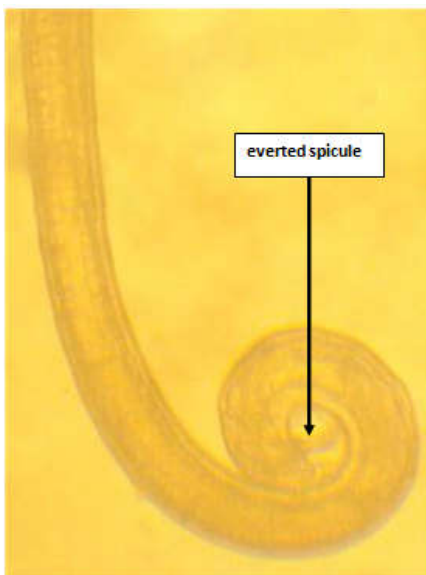
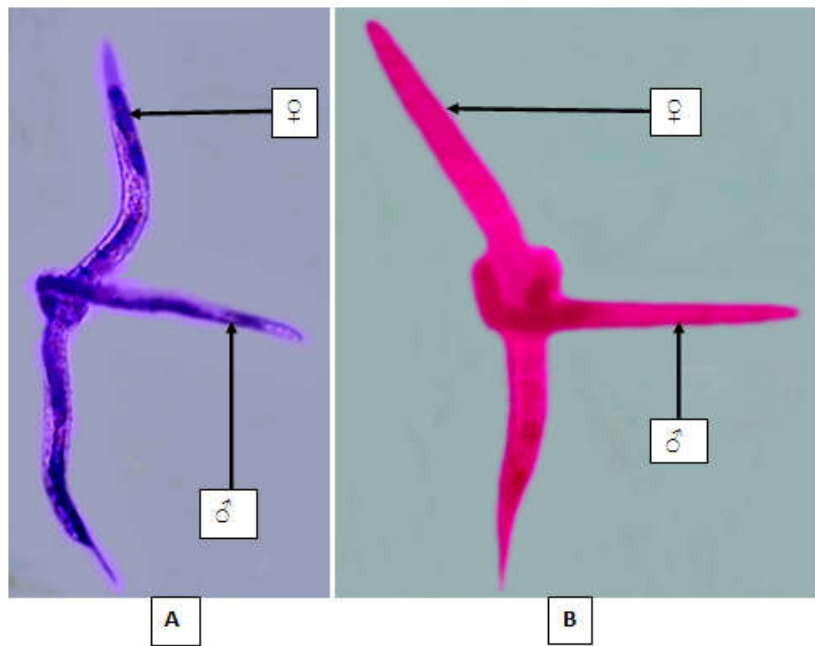


Figure 2c. The coiled posterior body part of a male *Strongyloides stercoralis* with an everted spicule



Figure 2e. The curved posterior body part of a male *Strongyloides stercoralis* with an everted spicule



Strongyloides stercoralis: (A), parasitic male (♂) & parasitic female (♀) in copulation isolated from a fresh stool sample of an HIV/AIDS patient under medical care in a hospital & microphotographed with a digital camera; and (B), free-living male (♂) & free-living female (♀) in copulation isolated and then microphotographed with a digital camera from the growth culture of this very species by inoculating in an sterilized set of topsoil placed in a petridish and incubated at 28° C

Figure 3. Copulation among the worms of *Strongyloides stercoralis*

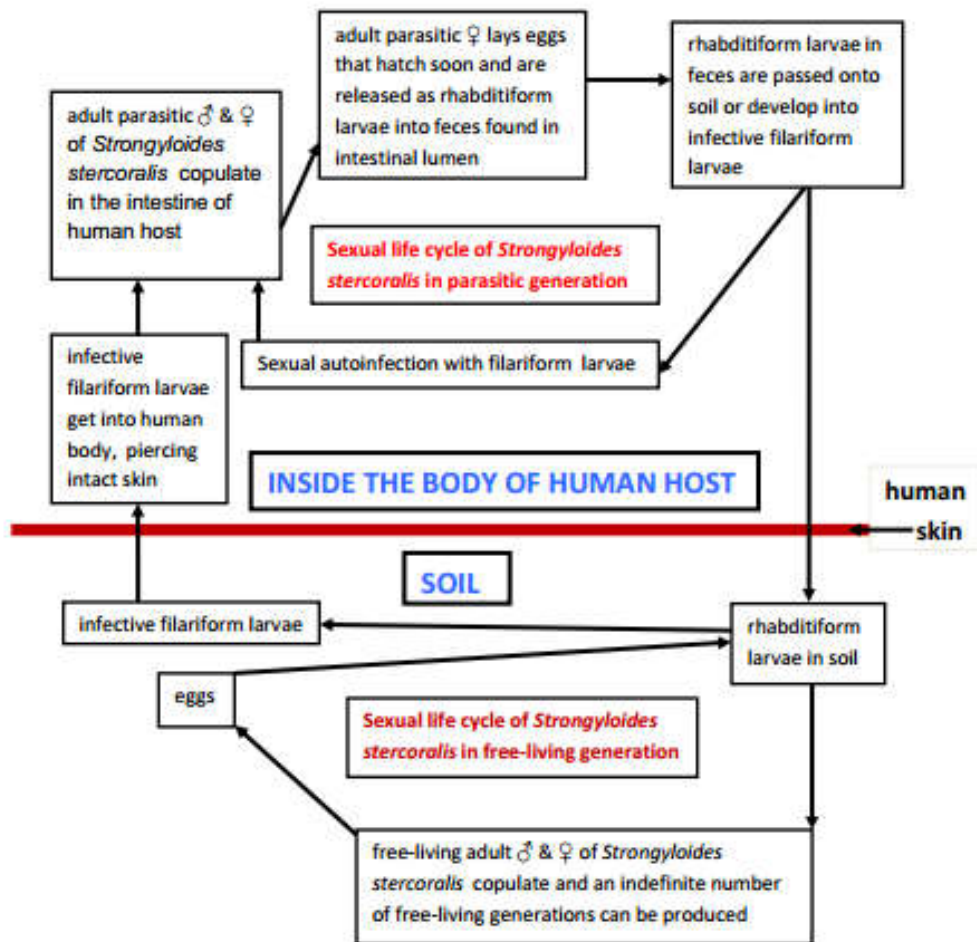


Figure 2. Complete integrated sexual life cycles of *Strongyloides stercoralis* in: parasitic generations in human host, and free-living generations in soil

It is only the posterior body part of male *Strongyloides stercoralis* that is taxonomically curved to varying degrees, from slight curvature up to more than 360° coiling. The spicule, with its tips that resemble the tips of a forcep, is used to open the vulva of the female to release male gametes into the female's reproductive tract at times of breeding and it is only at times of breeding that spicule is everted through cloaca from the spicule pouch. In *Strongyloides stercoralis* the exit of feces is called anus in females as the reproductive & digestive tracts do not have a common exit in females unlike in males. In males of *S. stercoralis*, the exit of the reproductive & digestive tracts is the same and such a common exit including this of male *S. stercoralis* is known as cloaca. The specimens in Figs 1; 2a to 2e, were isolated from fresh stool samples of participant student children in elementary schools, Dilla District, SNNPR, Ethiopia.

- The curved/coiled posterior body part of the male that coils around a specific body region of the female bears the genitals of the male everted at times of breeding (i.e., spicules everted out of spicule pouches found in cloaca).
- The specific body region of either parasitic or free-living female around which the curved/coiled posterior body part of the male coils bears vulva. The opening of vulva leads to a short muscular vagina which in turn leads to a pair of uteri of the adult female worm of *S. stercoralis*.

DISCUSSION

It has been believed that the type of reproduction of *Strongyloides stercoralis* in human hosts is parthenogenesis. In other words, parasitic males of *S. stercoralis* are never seen in human host until now. This is what has been written and reported: in modern textbooks of human/medical parasitology, in articles of famously reputable journals, and on the internet. However, the presence of the parasitic males (just as there are parasitic females) of *S. stercoralis* in human host had been shown in a demonstrative practical study project executed by the researcher of this paper (Feleke, 2014). Authors of modern textbooks of the subject stated that parthenogenesis was the only method of reproduction, still some others had concluded that protandrogony (i.e., hermaphroditism) was the actual method of reproduction for *S. stercoralis* in human host (Bogitsh, 2005). Neither the belief of parthenogenesis nor that of protandrogony is acceptable/true as each of them does not have any scientific evidence or persuasive scientific background. Actually the presence of the parasitic males of *S. stercoralis* in human host had been reported and published in 2014, being enough to block the epidemic spread of erroneous concepts of parthenogenesis and protandrogony. Anyhow, the report of this paper is crucial at global level to irreversibly delete the misleading generalizations of parthenogenesis and protandrogony without delay:

- From modern textbooks of human/medical parasitology,
- From related articles of journals,
- From concerned sites of internet, and
- From the minds of students of biology, and health sciences.

It is because of this massive strength of eradicating/eliminating these erroneous concepts from the scientific discipline of the subject that the title of this paper begins with the phrase "Active & concrete evidences".

This is so because when the free-living male & female copulate the curved/coiled posterior body part of the male coils around a specific body region of the female in order to ejaculate (introduce) the male gametes into the female reproductive tract through the opening of vulva. As it has been seen in the copulation of free-living male & female, the same positional form of copulation is spectacularly observed in the copulating parasitic male & female isolated from a fresh stool sample of a patient (Fig.3). Not only that, the specimens in Figs. 1; 2a to 2e, were also isolated from fresh stool samples of participant student children (proving that the parasitic male of *S. stercoralis* does actually/naturally resides inside the body of human host just like the parasitic female of *S. stercoralis*) in elementary schools, Dilla District, SNNPR, Ethiopia, 2006-2018. In conclusion, seeing the copulating of parasitic male & female of *S. stercoralis* with the observers' own eyes proved the fact that the method of reproduction of *S. stercoralis* was doubtlessly sexual. The usefulness of the integrated life cycles of the free-living & parasitic generations has been kept in mind, because efficient preventive measures against parasitosis and devising effective treatment depend on understanding the biology & life cycle of a parasite (which means understanding the nature of the disease).

Conflict of interest: I confirm that I don't have any competitive conflict of interest with anybody.

Financial support: The financial support to cover the cost of this study project was given by the Research & Dissemination Office of Dilla University.

Ethics: Ethical permission/clearance to perform the research work to contribute to the well-being of human subjects was obtained from Dilla University, the Office of Gedeo-Zone Administration, and the Directors of Elementary Schools of Dilla District.

Acknowledgements

I am very much thankful to Dilla Ethiopian Catholic Church for its assigning a medical doctor (Dr. Corazon B. Jaca FMA) for prescription and clinical supervision in the process of treating the infected participant student children. I am also grateful indeed to Dilla University for its providing me with the necessary fund to cover the cost of this study project and writing the letters of cooperation or ethical permission to the Directors of Elementary Schools of Dilla District.

REFERENCES

- Mitreva M, McCarter JP, Martin J, Dante M, Wylie T, Chiapelli B, *et al.* 2004. Comparative genomics of gene expression in the parasitic and free-living nematodes *Strongyloides stercoralis* and *Caenorhabditis elegans*. Genome Res (serial on the Internet). (cited 2012 Oct.24)14: (about 6p.). Available from: <http://genome.cshp.org/content/14/2/209.full>
- Concha R, Harrington WJR, Rogers AI. 2005. Intestinal strongyloidiasis: recognition, management, and determinants of outcome. *J Clin Gastroenterol.* 39: 203-11.
- Hunter CJ, Petrosyan M, Asch M. 2008. Dissemination of *Strongyloides stercoralis* in a patient with systemic lupus erythematosus after initiation of albendazole: a case report. *J Med Case Reports* (serial on the Internet). May 14 (cited

- 2012 Oct. 24); 2: (about 5 p.). Available from: <http://www.jmedicalcasereports.com/content/2//156>
- Gilles HM. 1996. Soil-transmitted helminths (geohelminths). In: Cook GC. editor. Manson's tropical diseases. 20th ed., London: WB Saunders; 1394-8, 1627.
- Paniker CKJ. 2007. Textbook of medical parasitology. 6th ed., New Delhi; Jaypee Brothers Medical Publishers; 169-74.
- Bogitsh BJ, Carter CE, Oeltmann TN. 2005. Human parasitology. 3rd ed., USA; Academic press 334-9.
- Dillard KJ, Saari SAM, Anttila M. 2007. *Strongyloides stercoralis* infection in a Finnish kennel. Acta Vet Scand (serial on the Internet). 2007 Dec 12 (cited 2012 Oct 24); 49: (about 5 p.). Available from: <http://www.actavetscand.com/content/49/1/37>
- Keiser PB, Nutman TB. 2012. *Strongyloides stercoralis* in the immunocompromised population. Clin Microbiol Rev (serial on the Internet). 2004 Jan (cited Oct 24); 17(1): (about 3 p.). Available from: [http://www.ncbi.nlm.nih.gov/...>Clin Microbiol Rev>v.17\(1\); Jan 2004](http://www.ncbi.nlm.nih.gov/...>Clin Microbiol Rev>v.17(1); Jan 2004)
- Nolan TJ, Bhopale VM, Schad GA. 1999. Hyperinfective strongyloidiasis: *Strongyloides stercoralis* undergoes autoinfective burst in neonatal gerbils. J Parasitol, 1999; 85: 286-9.
- Dionisio D, Manneschi LL, Lollo SD, Orsi A, Tani A, Esperti F. 2000. *Strongyloides stercoralis*: ultrastructural study of newly hatched larvae within human duodenal mucosa. J Clin Pathol., 53: 110-6.
- Massey HCJ, Nishi M, Chaudhary K, Pakpout N, Lok JB. 2003. Structure and developmental expression of *Strongyloides stercoralis*. Int J Parasitol., 33: 1537-44.
- Garg PK, Perry S, Dorn M, Hardcastle L, Parsonnet J. 2005. Risk of intestinal helminth and protozoan infection in a refugee population. Am J Trop Med Hyg (serial on the Internet). Mar 20 (cited 2012 Oct 24); 83(3): (about 4 p.). Available from: <http://www.ajtm.org/content/73/2/386>
- Siddiqui AA, Berk SL. 2012. Diagnosis of *Strongyloides stercoralis*. In: Ericsson CD, Steffen R, editors. Clin Infect Dis (serial on the Internet). 2012 Oct 15 (cited 24); 55(8): (about 8 p.). Available from: <http://cid.oxfordjournals.org/content/33/7/1040.full>
- Siegel MO, Simon GL. 2012. Is human immunodeficiency virus infection a risk factor for *Strongyloides stercoralis* hyperinfection and dissemination? PLoS Negl Trop Dis (serial on the Internet). Jul 31 (cited 2012 Oct 24); 6(7): (about 4 p.). Available from: [http://www.ncbi.nlm.nih.gov/...>PLoS Negl Trop Dis>v.6\(7\) ;Jul 2012](http://www.ncbi.nlm.nih.gov/...>PLoS Negl Trop Dis>v.6(7) ;Jul 2012)
- Ramanathan R, Nutman TB. 2008. *Strongyloides stercoralis* Infection in the Immunocompromised Host. Japan J Parasitol (serial on the Internet). 2008 May (cited 2012 Oct. 24); 10(2): (about 4 p.). Available from: <http://www.ncbi.nlm.nih.gov/pubmed/18462583>
- Poonam P, Jayshree RS, Acharya RS, Hema S, Govind B, Suresh TM. 1999. Fulminant fatal *Strongyloides stercoralis* infection in a postchemotherapy immuno-suppressed cancer patient. Med Pediatric Oncol, 33: 504-5.
- Jayshree RS, Hema S, Govind B, Suresh TM. 2001. *Strongyloides stercoralis* eggs in the stools during anticancer therapy. Indian J Gastroenterol., 20: 160-1.
- Kim J, Joo HS, Ko HM, Na MS, Hw ASH, Im JC. 2005. A case of fatal hyperinfective strongyloidiasis with discovery of autoinfective filariform larvae in sputum. Korean J Parasitol 2005; 43: 51-5.
- Fardet L, Genereau T, Poirot JL, Guidet B, Kettaneh A, Cabane L. 2007. Severe strongyloidiasis in corticosteroid-treated patients: case series and literature review. J Infect., 54:18-27.
- Kerepesi LA, Hess JA, Leon O, Nolan TJ, Schad GA, Abraham D. 2007. Toll-like receptor 4 (TLR4) is required for protective immunity to larval *Strongyloides stercoralis* in mice. Microb Infect., 9: 28-34.
- Rahif RH, Emara GY, Al-saqur IM. 2002. Epidemiological study of intestinal nematodes in dogs in Basrah (Iraq): prevalence of helminthic ova in the fecal deposits. Iraqi J Vet Sci., 16: 71-9.
- Cheesbrough M. 1998. District laboratory practice in tropical countries. Part 1. India; Cambridge University Press; 214-5.
- Feleke E. 2014. Epidemiological studies on *Strongyloides stercoralis* at Dilla District, Ethiopia. Afro-Egypt J Infect Endem Dis., 4(2): 69-79.
